

Malignant infantile osteopetrosis with cleft lip— a case report

Pabbati Jayalakshmi, Preethi Subramaniam, Regina Divya, Aravind

Department of Pediatrics, MediCiti Institute of Medical Sciences, Ghanpur, Medchal, Hyderabad, Telangana, India.
Correspondence to: Regina Divya, E-mail: twtbird4@gmail.com

Received May 4, 2015. Accepted May 22, 2015

Abstract

Malignant infantile osteopetrosis (MIOP), a rare congenital disorder of bone resorption, is caused by the failure of osteoclasts to reabsorb immature bones. We report a 3-month-old female child with cleft lip who was referred to the pediatric department for consultation. She was born to consanguineous parents, and the elder sibling expired at the age of 3 years owing to recurrent respiratory tract infections and hydrocephalus. On examination, we found pallor and hepatosplenomegaly. On follow-up, we came to know that she exhibited delayed developmental history and bilateral optic atrophy. Skeletal radiographs showed dense bones with “bone-in-bone” appearance. The overall clinical features and radiological findings of these patients were sufficient to arrive at the diagnosis of MIOP.

KEY WORDS: Osteopetrosis, optic atrophy, pallor, radiological findings

Introduction

The term osteopetrosis is derived from Greek “osteo” meaning bone and “petrosis” meaning stone. It was first described in 1904 by a German radiologist Albers-Schönberg^[1]; hence, the disease also gets the name Albers-Schönberg disease. Osteopetrosis is classified into three forms as autosomal recessive, autosomal dominant, and X-linked inheritance.

An elevated skeletal density and abundant formation of the bones are the features that characterize osteopetrosis, which is a rare genetic disorder; it destroys the medullary cavity, resulting in extramedullary hematopoiesis, hepatosplenomegaly, anemia, and thrombocytopenia. Nerve compression arises owing to the excessive growth the cranial nerve foramina, which frequently affects the optic, auditory, and facial nerves. Growth retardation and recurrent infections are also common.^[2] Severe malignant infantile osteopetrosis

(MIOP) is fatal without curative therapy. Seventy percentage of children with MIOP die by the age of 6 years, and almost 100% die before the age of 10 years.

Case Report

A 3-month-old female baby brought for cleft lip repair was referred to the Department of Pediatrics. On physical examination, her weight was 4.2 kg, head circumference 39 cm, and length 53 cm; she revealed pallor, cleft lip, hepatomegaly (span 8 cm), and grade II splenomegaly (palpable 6 cm below left costal margin from midclavicular line).

With the detailed history, we found that this girl was born by a full-term normal delivery to a consanguineously married couple. Her birth weight was 2.7 kg, and she was the third in birth order. The first sibling, a male child, showed failure to thrive, pallor, macrocephaly, global developmental delay, hepatosplenomegaly, recurrent history of lower respiratory tract infections, and expired at 3 years of age with sepsis. The second sibling, a female child, is thriving well.

Laboratory investigations showed anemia (Hb, 8.1 gm/dL), thrombocytopenia (80,000) with normal WBC count (8,500/mm³). Peripheral blood smear showed microcytic, hypochromic red blood corpuscles with immature white blood cells (WBCs; myleocytes, metamyelocytes, and bandforms) and normoblasts (3–4/100 WBC). Bone marrow aspiration revealed erythroid hyperplasia. Hemoglobin electrophoresis was normal. Inborn error of metabolism workup was normal.

Access this article online

Website: <http://www.ijmsph.com>

DOI: 10.5455/ijmsph.2015.04052015345

Quick Response Code:



International Journal of Medical Science and Public Health Online 2015. © 2015 Regina Divya. This is an Open Access article distributed under the terms of the Creative Commons Attribution 4.0 International License (<http://creativecommons.org/licenses/by/4.0/>), allowing third parties to copy and redistribute the material in any medium or format and to remix, transform, and build upon the material for any purpose, even commercially, provided the original work is properly cited and states its license.

Investigation for TORCH infections showed positive only for rubella IgG antibody. Liver biopsy was planned to rule out glycogen storage disorder. As the parents were not willing, the child was sent home with oral iron and folic acid supplementations with the advise to come for review after 2 weeks, but the child was not brought to the hospital for follow-up.

Parents brought the child at the ninth month of age, after first visit to OPD, with complaints of fever, cold, cough, breathing difficulty, and repeated attacks of upper respiratory tract infections in past. Mother also gave global developmental delayed history.

On examination, she was tachypneic with intercostal and subcostal retractions and bilateral wheeze on auscultation. Her pallor (Hb, 6 gm/dL), hepatomegaly (liver span was 11 cm), and splenomegaly (grade III, palpable 9 cm below costal margin) conditions were increased [Figure 1]. She was not holding neck, not following objects, and not responding to sounds. Eye examination revealed roving eye movement, inability to fix the gaze, and the pupils were dilated with sluggish reaction to light. A pale optic disc (optic atrophy) was seen on direct ophthalmoscopy. She was admitted in the hospital with provisional diagnosis of osteopetrosis with severe bronchiolitis.

Workup for osteopetrosis was done by taking X-rays. The anteroposterior [Figure 2] and lateral skull radiographs [Figure 3] showed marked sclerosis with thickening of the orbital rims, skull base, and calvarium with a loss of distinction between the cortex and medulla. A lateral radiograph of the spine [Figure 4] showed diffusely increased bone density

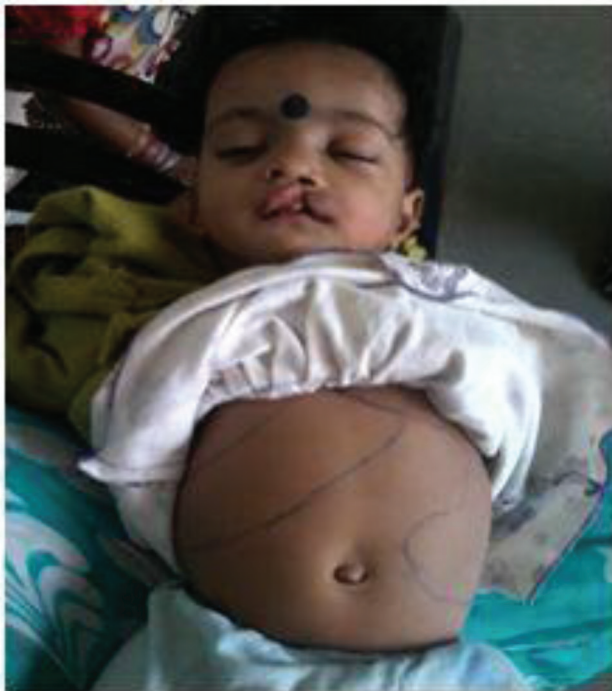

Figure 1: Clinical photograph.

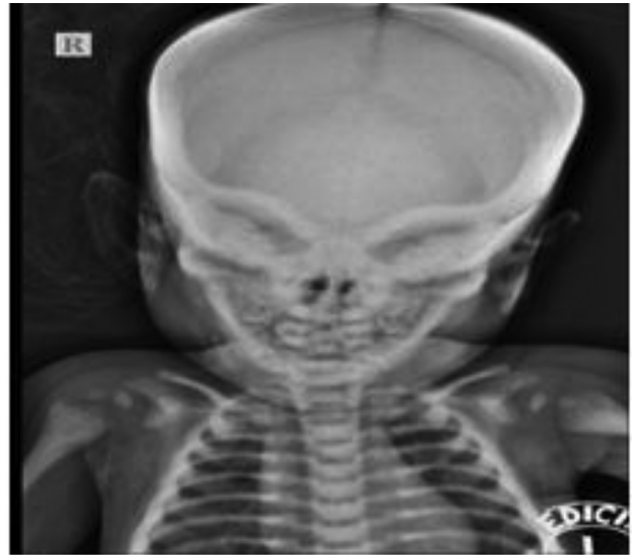


Figure 2: Anteroposterior view of skull.

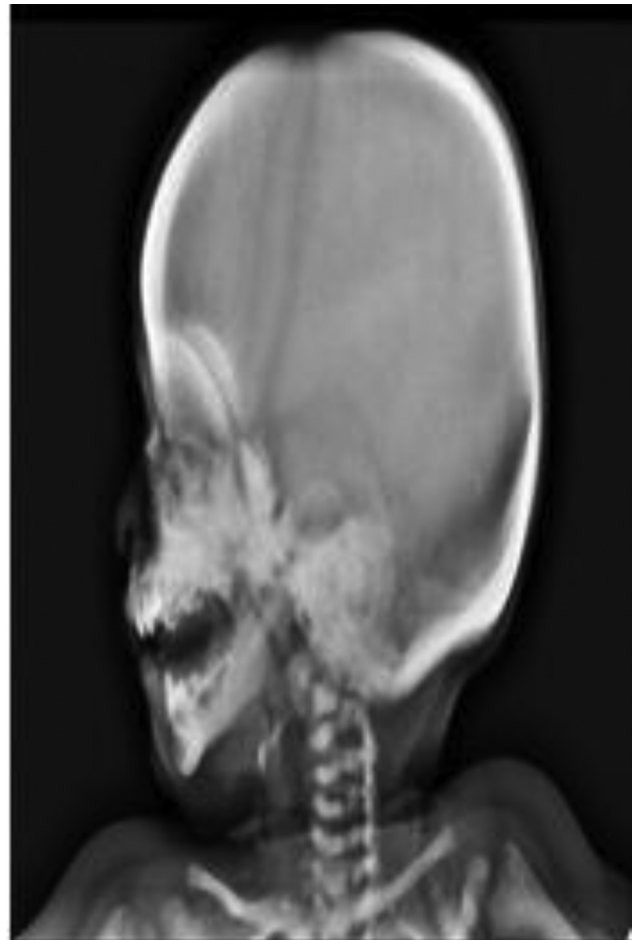

Figure 3: Lateral view of skull.

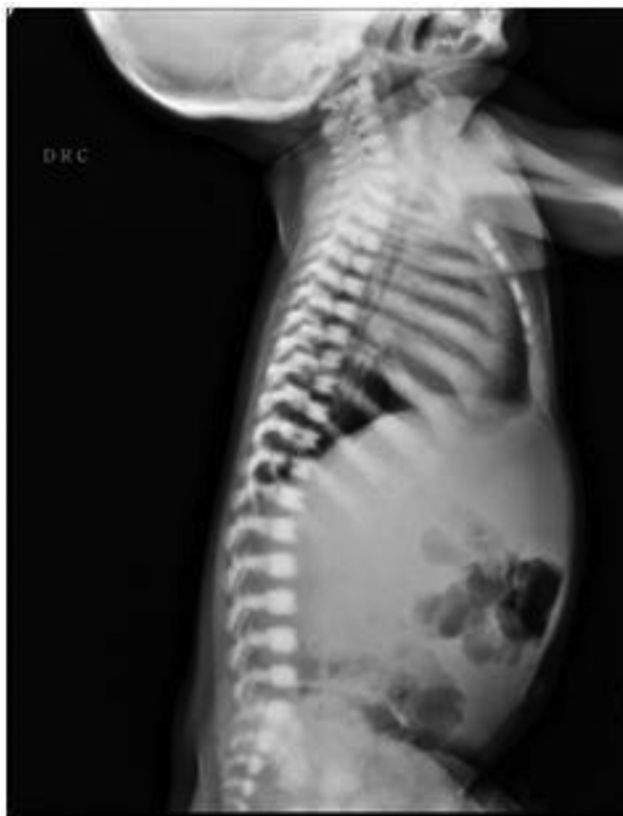

Figure 4: Lateral view of spine.

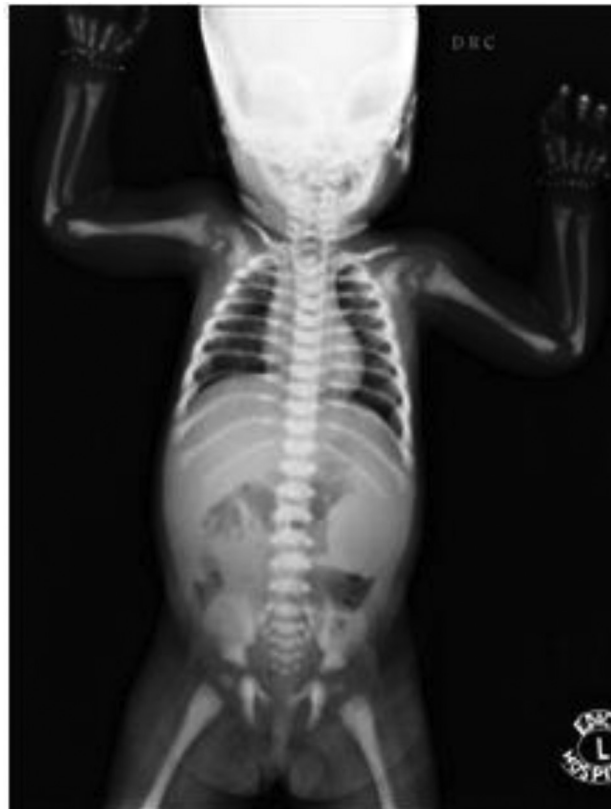


Figure 5: Infantogram.

and reduced marrow spaces in the vertebral bodies. Anteroposterior radiograph of the infant [Figure 5] showed diffusely increased bone density in femur with reduced marrow space and with characteristic “bone-in-bone” appearance. Her serum calcium and phosphorus were normal with elevated alkaline phosphatase (750 units). Brainstem evoked response audiometry (BERA) done showed sensory neural hearing loss. On the basis of the age of onset of clinical features and investigations, she was diagnosed as a case of MIOP. Genetic testing was not done for the *TCIRG1* gene.

The patient received symptomatic and supportive treatment including O_2 , IV fluids, and antibiotic therapy. Patient was advised for bone marrow transplantation (BMT), which was not done owing to the cost. She was discharged with iron and folic acid, calcium, and vitamin D supplementations.

Discussion

Osteopetrosis is very rare disease in most populations. It has an incidence of 1 in 2,50,000 births. It is much more common in consanguineous population. Severe MIOP is the autosomal recessively inherited form of this disease that generally presents at birth^[3,4] or within the first year of life. It is severe when compared with the autosomal dominant

form.^[5] Our patient presented the symptoms at the age of 3 months.

In MIOP, because of the failure of osteoclast function, the osteoblasts take up all the space for the bone marrow with new bone, interferes with medullary hematopoiesis and leads to secondary expansion of extramedullary hematopoiesis sites such as the liver and spleen. So, these children become anemic and thrombocytopenic, and they are unable to fight infections effectively without medical intervention.

The most commonly observed neurological manifestations of osteopetrosis are secondary to the obstruction of the foramina, through which the cranial nerves, spinal cord, and major blood vessels transverse the skull, resulting in blindness, hearing loss, facial palsy, and hydrocephalus.^[6,7] Distinct from these compressive phenomena, some patients with autosomal recessive osteopetrosis variants (neuropathic ARO) display signs of primary neurodegeneration including primary seizures in the setting of normal calcium levels, developmental delay, hypotonia, retinal atrophy, and sensorineural deafness.^[6] Our patient developed blindness, deafness, and global developmental delay.

Characteristic radiographic findings in osteopetrosis include a marked increase in bone density and a bone-within-a-bone appearance.^[8] The skeletal survey of our patient was specific for radiologic findings of osteopetrosis.

Doffinger et al. described a new form of osteopetrosis associated with ectodermal anhydrotic dysplasia, immunodeficiency, and lymphedema. Sometimes, there is a related cleft lip and/or palate. The disease has an X-linked recessive pattern of inheritance and results from *IKBKG* gene-NF- κ B signaling abnormality.^[9]

Genetic testing can be used to confirm the diagnosis and differentiate between different subtypes of osteopetrosis, providing additional information regarding prognosis, response to treatment, and recurrence risks.^[10] Genetic testing was not done owing to cost, and even with genetic test, 30% of them remain genetically unrecognized.^[11]

On the basis of clinical history, radiographic findings, our case was diagnosed as the malignant infantile type. Management of patients with osteopetrosis requires a comprehensive approach to characteristic clinical problems including hematological, recurrent infections, bone complications, and neurological sequel.^[12]

At present, hematopoietic stem cell transplantation (HSCT) offers the only chance of cure for MIOP treatment.^[13] It should be performed early before the onset of irreversible neurologic impairment. In our case, HSCT was not performed, as the parents were not inclined for the procedure. Therefore, the treatment was largely supportive and was aimed at providing surveillance and symptomatic management of complications such as antibiotic therapy, calcium and vitamin D supplementation, and nutritional measures.

Genetic counseling is important. All cases are likely to be inherited in an autosomal recessive fashion. Thus, there is a one in four (25%) risk of having another affected child with each subsequent pregnancy.

Antenatal diagnosis in families with MIOP is possible by using molecular analysis much early (chorionic villus sampling, 11–13 weeks), providing that a genetic etiology has been found in the proband.^[14] Radiographs^[15] may be useful in the third trimester, thus allowing HSCT before the age of 3 months with the aim of improving neurological outcomes. Prenatal diagnosis is planned for the forthcoming pregnancies.

Conclusion

MIOP should be kept in mind as a rare cause of anemia with hepatosplenomegaly. Early diagnosis and timely HSCT are the only curative approaches for an otherwise fatal disease.

References

1. Albers-Schönberg HE. Röntgenbilder einer seltenen Knochenerkrankung. *Munch Med Wochenschr* 2005;5:365–68.
2. Gerritsen EJ, Vossen JM, van Loo IH, Hermans J, Helfrich MH, Griscelli C, et al. Autosomal recessive osteopetrosis: variability of findings at diagnosis and during the natural course. *Pediatrics* 1994;93(2):247–53.
3. Engiz O, Kara S, Bagrul D, Lahr G, Alioglu B, Arikan I, et al. Infantile malignant osteopetrosis: a rare cause of neonatal hypocalcemia. *J Pediatr Endocrinol Metab* 2012;25(11–12):1205–7.
4. Kurtoglu S, Hatipoglu N, Canpolat M, Altunay C. Malignant infantile osteopetrosis presenting with neonatal hypocalcemia. *Erciyes Med J* 2009;31(1):70–3.
5. Jakub T, Teitelbaum SL, Orchard PJ. Osteopetrosis. *N Engl J Med* 2004;351(27):2839–49.
6. Al-Tamimi YZ, Tyagi AK, Chumas PD, Crimmins DW. Patients with autosomal-recessive osteopetrosis presenting with hydrocephalus and hindbrain posterior fossa crowding. *J Neurosurg Pediatr* 2008;1(1):103–6.
7. Steward CG. Neurological aspects of osteopetrosis. *Neuropathol Appl Neurobiol* 2003;29(2):87–97.
8. Arun S, Singh A, Chavan M. Autosomal recessive osteopetrosis: case report of two siblings. *Oral Radiol* 2008;24(2):80–4.
9. Glorieux FH, Pettifor JM, Jüppner H (Eds.). *Pediatric Bone: Biology and Diseases*. California: Academic Press, 2003. p. 477. ISBN: 978-0-12-382040-2.
10. Stark Z, Savairayan R. Osteopetrosis. *Orphanet J Rare Dis* 2009;4(1):5.
11. Del Fattore A, Cappariello A, Teti A. Genetics, pathogenesis and complications of osteopetrosis. *Bone* 2008;42(1):19–29.
12. Ahmad I, Abbas SZ, Haque F, Rashid M, Ahmad SA. Osteomyelitis of mandible—a rare presentation of osteopetrosis. *Indian J Radiol Imaging*. 2006;16(2):253–6.
13. Essabar L, Meskini T, Ettair S, Erreimi N, Mouane N. Malignant infantile osteopetrosis: case report with review of literature. *Pan Afr Med J* 2014;17:63.
14. Kapelushnik J, Shalev C, Yaniv I, Aker M, Carmi R, Cohen Z, et al. Osteopetrosis. A single centre experience of stem cell transplantation and prenatal diagnosis. *Bone Marrow Transplant* 2001;27(2):129–32.
15. Ogur G, Ogur E, Celasun B, Baser I, Imirzalioglu N, Ozturk T, et al. Prenatal diagnosis of autosomal recessive osteopetrosis, infantile type, by X-ray evaluation. *Prenat Diagn* 1995;15(5):477–81.

How to cite this article: Jayalakshmi P, Subramaniam P, Divya R, Aravind. Malignant infantile osteopetrosis with cleft lip—a case report. *Int J Med Sci Public Health* 2015;4:1784-1787

Source of Support: Nil, **Conflict of Interest:** None declared.